

Case Report**Adenosquamous Variant of Metaplastic Carcinoma of Breast****Avash Koirala^a, Clement Wilfred D.^b, Prasanna Shetty B.^c**^aPost Graduate ^bAssociate Professor ^cProfessor and HOD, Department of Pathology, M.S. Ramaiah Medical College, Bengaluru, Karnataka 560054, India.**Abstract****Corresponding Author:****Clement Wilfred Devdass,**
Associate Professor,
Department of Pathology,
M.S. Ramaiah Medical College,
Bengaluru, Karnataka 560054.
India.
E-mail:
clement.wilfred@yahoo.com**(Received on 23.01.2018,**
Accepted on 09.02.2018)**Introduction:** Metaplastic carcinoma of breast belongs to a diverse class of neoplasm constituting the rarest histological variant of invasive ductal carcinoma. Adenosquamous carcinoma of breast is a rare tumour which is a variant of metaplastic carcinoma, comprising 0.3% of breast carcinomas.**Case Report:** Here, we report a case of adenosquamous variant of metaplastic carcinoma of breast in a 61 years old female who presented with a lump in the right breast.**Conclusion:** The present case highlights that although adenosquamous carcinoma of breast is rare, we should be aware of this possibility and include it in the differential diagnosis whenever appropriate.**Keywords:** Metaplastic; Adenosquamous; Carcinoma.**Introduction**

Metaplastic carcinoma of breast belongs to a diverse class of neoplasm consisting of mixture of adenocarcinoma and areas of squamous cell, spindle cell and/or mesenchymal differentiation, accounting for less than 1% of all invasive carcinomas [1].

Adenosquamous carcinoma of breast is a rare tumour included in WHO classification of breast cancer, as a subtype of metaplastic carcinoma, constituting 0.3% of all breast carcinomas [2,3]. Adenosquamous carcinoma is characterized by areas of well-developed tubule/gland formation intimately admixed with widely dispersed solid nests of squamous differentiation [4].

Adenosquamous carcinoma are divided into low grade and high grade. Low grade adenosquamous carcinoma has less nuclear anaplasia, do not metastasize and have an overall good prognosis [3]. In contrast, high grade

adenosquamous are quite aggressive and show lymph node metastasis at the time of diagnosis.

Case Report

A 61 years old female, presented with a lump in the right breast for 8 months. Physical examination revealed a lump which was hard, measured 6x5 cm with nipple retraction and palpable ipsilateral axillary lymph nodes. The contralateral breast and axillary nodes were normal.

Sonomammography revealed an ill-defined lesion in the upper right quadrant with axillary lymphadenopathy (Figure 1). Trucut biopsy confirmed the diagnosis of invasive ductal carcinoma NOS following which she underwent modified radical mastectomy and the specimen was sent for histopathological examination.

On gross examination, radical mastectomy specimen measured 15x13x4 cm. Cut surface revealed a pearly white lesion in upper outer quadrant (Figure 2).

Microscopic examination showed foci of architecturally confluent glandular formation with an adjacent desmoplastic stroma (Figure 3). Also seen were tumor composed of nests, jagged islands of mild to moderately

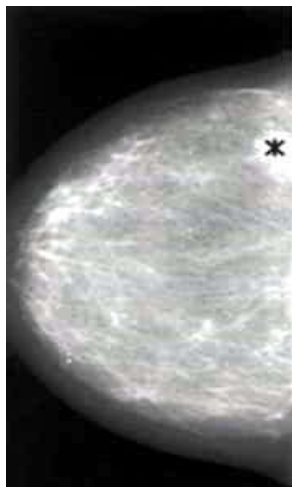


Fig. 1: Mammogram of breast showing radiodense lesion shown by *which has speculated margins and microlobulations suggestive of carcinoma breast

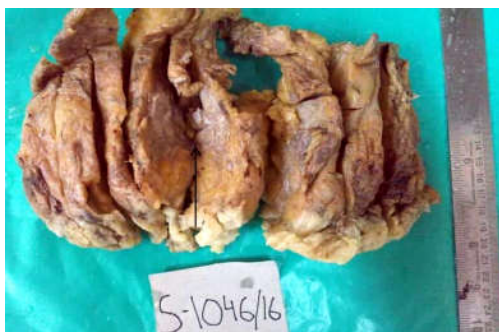

Fig. 2: Modified radical mastectomy specimen measuring 15x13x4 cm. Cut surface revealed pearly white lesion in upper outer quadrant (arrow)

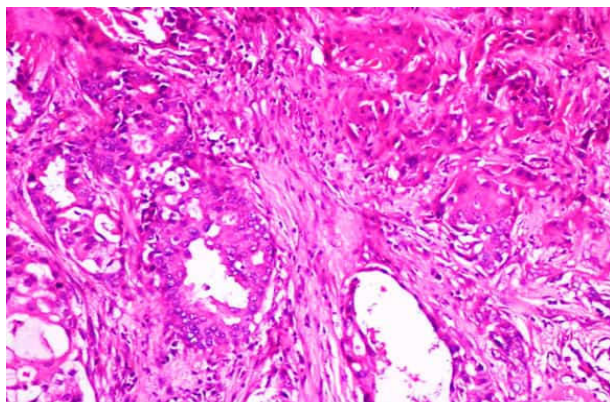


Fig. 3: Photomicrograph showing foci of architecturally confluent glandular formation with desmoplastic stroma (H&E; 10x)

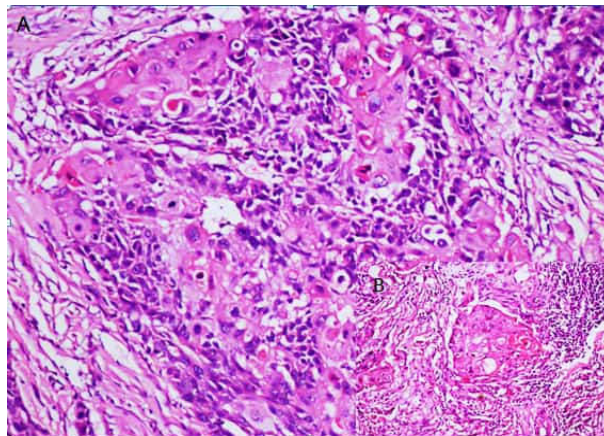


Fig. 4(A): Photomicrograph showing parts of a tumor composed of nests, jagged island of mild to moderately pleomorphic cells with a squamoid appearance (H&E; 10x); (B) – [Inset: Photomicrograph showing foci of keratin pearl formation with a few dyskeratotic cells (H&E; 10x).

pleomorphic cells with a squamoid appearance (Figure 4A). There were foci of keratin pearl formation with a few dyskeratotic cells (Figure 4B). Ductal carcinoma insitu with solid and cribriform growth pattern was also seen. The diagnosis of adenosquamous carcinoma was given.

The immunohistochemical staining showed triple negative for ER, PR, and Her2 neu expression and showed strong positive for cytokeratin.

Discussion

Adenosquamous breast carcinoma was first described by Rosen in 1987 and later in a follow up study by Van Hoven in 1993 [5]. Adenosquamous carcinoma presents as a palpable mass and has been found in women whose age ranges from 31 to 87 years [3].

Adeosquamous carcinoma is difficult to diagnose from other benign and invasive tumors on noninvasive investigations. On imaging only the benign nature of the lesion is observed. These tumors do not exhibit much cytological atypia, despite the infiltrative nature of these tumors, so making it difficult to diagnose on cytology.

On trucut biopsy, the infiltrative nature of the tumor cannot be observed. So, diagnosis is usually made histologically on excision biopsy specimen [6]. At gross examination, adenosquamous carcinoma tends to display a stellate or infiltrative configuration, with poorly defined borders. Microscopically, the carcinomatous component is characterized by small glandular structures, with rounded rather than angulated contours, and solid cords of epithelial cells, which may contain squamous cells, squamous pearls or squamous nests formation. The invasive neoplastic component typically shows long, slender, extensions at the periphery and infiltrate in

between the normal breast structures, features which have been associated with inadequate local excision and high incidence of recurrence.

Adenosquamous carcinoma is consistently negative for ER, PR Her2-neu expression, hence may be a useful diagnostic tool. Myoepithelial and cytokeratin stains are positive, but the extent of staining is highly variable. SMA, p63, calponin and CD10 show variable degree of positivity [2,7].

The study conducted by Khatib et al., who reviewed one case of low-grade adenosquamous carcinoma of breast, showed triple negative for ER, PR, Her2 neu expression. SMA and calponin were positive and highlighted the myoepithelial cells, but p63 showed focal positivity [8]. Similarly, our case showed triple negative for ER, PR, Her2 neu expression but showed strong positivity for cytokeratin expression.

The study conducted by Geyer et al., who observed five cases of adenosquamous carcinoma of breast, all of them belonged to 54 to 76 years of age [2]. Similarly, our case was 61 years old.

The overall prognosis of adenosquamous carcinoma is good but it has a tendency to locally recur depending on the adequacy of local excision. So, complete local excision or mastectomy is usually recommended. Adenosquamous carcinoma should always be differentiated from tubular carcinoma, infiltrating syringomatous adenoma of the nipple and adenomyoepithelioma [8].

Conclusion

Adenosquamous carcinoma is a rare entity, has risk of local recurrence after incomplete excision and has low metastatic potential. In conclusion, adenosquamous carcinoma should always be kept in the differential diagnosis whenever appropriate.

Acknowledgement

Nil

Conflict of Interest: Nil

References

1. Altaf F, Mokhtar G, Emam E, Bokhary R, Mahfouz N, Al Amoudi S et al. Metaplastic carcinoma of the breast: an immunohistochemical study. *Diagnostic Pathology*. 2014;9(1):139.
2. Geyer F, Lambros M, Natrajan R, Mehta R, Mackay A, Savage K et al. Genomic and immunohistochemical analysis of adenosquamous carcinoma of the breast. *Modern Pathology*. 2010;23(7):951-960.
3. Swathy P. Adenosquamous Variant of Metaplastic Carcinoma of Breast – An Unusual Histological Variant. *Journal of Clinical and Diagnostic Research*. 2015;9(2):ED05-ED06.
4. I.O. Ellis, S.J. Schnitt, X. Sastre-Garau, G. Bussolati, F.A. Tavassoli, V. Eusebi et al. Tumors of the breast. In: Tavassoli AF, Devilee P, editors. *World Health Organization Classification of Tumours. Pathology and Genetics of Tumors of the Breast and Female Genital Organs*. Lyon: IARC Press; 2003.p.9-112.
5. Tan Q, Chuwa E, Chew S, Lim-Tan S, Lim S. Low-grade adenosquamous carcinoma of the breast: A diagnostic and clinical challenge. *International Journal of Surgery*. 2015;19:22-26.
6. Garg S, Kalhan S, Garg N, Rana S, Gill M, Sangwaiya A. Low-grade adenosquamous carcinoma breast in 55-years-old female: A diagnostic challenge. *Clinical Cancer Investigation Journal*. 2015;4(2):230-232.
7. Kawaguchi K, Shin S. Immunohistochemical Staining Characteristics of Low-grade Adenosquamous Carcinoma of the Breast. *The American Journal of Surgical Pathology*. 2012;36(7):1009-1020.
8. Khatib Y, Patel R, Mulla A, Francis C. Low-grade adenosquamous carcinoma of the breast: A case report and review of literature. *Clinical Cancer Investigation Journal*. 2014;3(5):408.